



Adenoid tissue rhinopharyngeal obstruction grading based on fiberendoscopic findings: a novel approach to therapeutic management

Pasquale Cassano^{a,1}, Matteo Gelardi^{b,2}, Michele Cassano^{b,*},
M.L. Fiorella^b, R. Fiorella^b

^a Department of Otorhinolaryngology, University of Foggia, Foggia, Italy

^b Department of Otorhinolaryngology, University of Bari, Bari, Italy

Received 6 March 2002; received in revised form 26 July 2003; accepted 27 July 2003

KEYWORDS

Nasal obstruction;
Adenoid hypertrophy;
Rhinopharyngeal
fiberendoscopy;
Adenoidectomy;
Adenoid grading;
Upper respiratory tract
phlogosis

Summary Objective: A grading into four classes of hypertrophied adenoid rhinopharyngeal obstructions in children on the basis of fiberendoscopic findings to outline an effective therapeutic program according to this classification. **Methods:** Ninety-eight children with chronic nasal obstruction and oral respiration were examined by anterior rhinoscopy, and fiberendoscopy. During the investigation, the fiberendoscopic images of the choanal openings were divided into four segments from the upper choanal border to the nasal floor. In view of clinical findings, 78 patients also underwent active anterior rhinomanometry. **Results:** In eight patients (8.2%), the fiberendoscopic imaging revealed that the adenoid tissue occupied only the upper segment in the rhinopharyngeal cavity (<25%). Therefore, choanal openings were free (first degree obstructions). In 20 patients (20.4%), the adenoid tissue was confined to the upper half (<50%) of the rhinopharyngeal cavity (second degree obstructions) and in 63 patients (64.3%) the tissue extended over the rhinopharynx (<75%) with obstruction of choanal openings and partial closure of tube ostium (third degree obstructions). Only in seven cases (7.14%), the obstruction was almost total. As a consequence, both the tube ostium and the lower choanal border could not be observed (fourth degree obstructions). **Conclusions:** In the first two classes of obstructions, characterized by moderate or discrete adenoid hypertrophy, adenoidectomy should not be performed. In these conditions, the causes of possible nasal obstructions are usually due to either dysmorphic, allergic or phlogistic pathologies. For the fourth degree adenoid obstructions, surgery is always recommended. The most important therapeutic problems occur in the third degree obstructions which include most patients who suffered from hypertrophied adenoids. Moreover, the therapeutic strategy can be conditioned not only by nasal respiratory difficulties but also by frequent concomitant complications such as otitis, sinusitis, sleep apnea, etc. These disorders may be caused by both nasal obstruction and/or phlogistic problems (adenoiditis).

© 2003 Elsevier Ireland Ltd. All rights reserved.

*Corresponding author. Present address: via Crispi 34/C, 70123 Bari, Italy. Tel.: +39-080-5235508; fax: +39-080-5211318.

E-mail address: michcass@tiscali.it (M. Cassano).

¹Present address: via Crispi 34/C, 70123 Bari, Italy. Tel.: +39-080-5235508; fax: +39-5211318.

²Present address: viale della Resistenza 124, 70125 Bari, Italy.

1. Introduction

Sub-continuous and partial nasal obstruction is a very common condition in children. But it usually causes no significant respiratory difficulties. Therefore, the disorder is usually considered a minor illness which will disappear with puberty.

The obstruction may be due to anatomic, physiologic, and phlogistic factors. The first include incomplete development of nasal cavities, septal deviation, etc., the second and the third nasal respiratory cycle and rhino-sinusitis, respectively. However, the most ascertained recurrent cause is adenoid hypertrophy. This condition, characterized by marked proliferation of lymphoreticular tissue [1], is particularly frequent in 4–6-year-old children (Fig. 1).

In 25% of the cases, nasal obstruction brings about pathologic conditions of such an entity and duration as to produce a series of local phlogistic manifestations such as rhinosinusitis, otitis [2–4] and/or peripheral diseases including phlogistic and dis-reactive bronchopulmonary disorders. These ailments can influence the patient's quality of life as well as interfere with their psycho-physical development.

Whether hypertrophic adenoids can cause sleep disorders as snoring and sleep apnoea [5], which, in turn, may generate serious diseases as cardiac, pulmonary affections [6] and even death in sleep in younger children, is still under debate. In fact, other disorders may be the cause of the pathologies often ascribed to sleep disorders [7–18].

The influence of adenoid hypertrophy may be less serious on facial block malformations (malocclusion, ogival palate, etc.). These appear related to a series of hereditary skeleton modifications [19]. Nevertheless, it cannot be excluded that oral respiration, if lasting, might be an aggravating factor in the development of maxillary malformations.

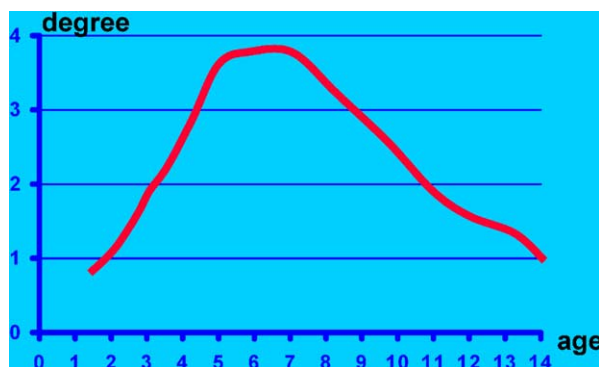


Fig. 1 Degree of adenoid hypertrophy related to the age.

Therefore, chronic and severe nasal obstructions have to be carefully evaluated and treated as soon as possible.

Clinical diagnosis of adenoid hypertrophy by conventional methods is rather difficult owing to obstacles met in performing the objective examination of the rhinopharyngeal cavity (posterior rhinoscopy) in young children.

Radiological evaluation of the rhinopharynx conformation and contents is often difficult to carry out in infants. The value of this technique should be better studied. In fact, in many cases we found no direct correlation between the entity of the obstruction evidenced by X-ray and the functional ailment.

At present, transnasal fiberendoscopic examination of the nasopharyngeal cavity with a flexible endoscope appears to be a valid diagnostic method. This approach requires little collaboration from the patients. It is risk-free and allows a precise definition of site, nature and entity of obstruction [20–24]. Small diameter fiberendoscopes allow to examine very young subjects. As well known, full collaboration of a child can only be had at 4–5 years of age.

This technique has been used successfully over the last 10 years for diagnosis of nasal and rhinopharynx pathologies in pediatric age.

In our practice, we studied the obstructions caused by adenoid vegetation and we have drawn up a simple classification that may be very useful for a therapeutic program for pediatricians and otolaryngologists. In this article, we report the results of our experience on nasal obstructions due to adenoid tissue and try to define a reliable diagnostic and therapeutic strategy.

2. Material and methods

The study includes 98 children, 77 males and 21 females aged 3–14 years (mean age: 5.3 years) with chronic oral respiration and/or nasal obstruction often complicated by nasosinusitis, and otologic infections or sleep disorders.

Patients with obstruction due to anatomic malformations (choanal atresias or diaphragms, septal deviations), were excluded. Anterior rhinoscopy was performed on all the patients preliminary.

After washing nasal cavities with a tepid sterile physiologic solution to remove secretions or scabs, and decongesting them with an oxymetazoline solution in the subjects with turbinate hypertrophy, a fiberendoscopy was performed with a flexible endoscope. In two subjects, local anesthesia was requested by the parents (lidocaine clorhydrate 10%). Most patients collaborated fully; in a third of

the cases it was necessary to immobilize the head of patients during the investigation. In 80 subjects (81.6%), we managed to perform an active anterior rhinomanometry at a distance of 24–48 h from endoscopic tests, which, as it is well-known, can cause vasomotory reaction. The test was carried out after nasal cavities cleaning, both in normal condition and after turbinate decongestion.

Patients reporting sleep disorders (snoring, agitated sleep, sleep apnoeas, etc.) were examined with a full night polysomnogram study so as to exclude any possible apnoeic obstructive pathology.

3. Results

3.1. Anterior rhinoscopy

In 41 subjects (41.8%), the test was normal; a bilateral turbinate hypertrophy was evidenced in 57 subjects (58.2%) with mucous-purulent or clearly purulent exudates in the nasal cavities in 38.

3.2. Rhinopharynx fiberendoscopy

In eight patients (8.2%), the fiberendoscopic image appeared more or less normal, evidencing scarce adenoid tissue involvement in rhinopharynx. As a result, choanal opening was free.

In these subjects, the adenoid obstruction was classified as first degree. In this group, one subject was <4 years old and seven >10 years old.

In 20 patients (20.4%) aged 4–12 years, the adenoid tissue appeared confined to the upper half of rhinopharyngeal cavity, with sufficiently pervious choanas and perfect visualization of tube ostium (adenoid obstructions of second degree).

In 63 patients (64.3%) aged 3–5 years, adenoid vegetation took up about 75% of the rhinopharynx with considerable obstruction of choanal opening, free only in the inferior area, and partial involvement of tube ostium (adenoid obstruction of third degree).

In seven patients (7.14%) aged 3–7 years, obstruction was practically complete. As a result, the adenoid tissue reached the lower choanal border and impeded the visualization of the tube ostium (adenoid obstruction of fourth degree) (Figs. 2 and 3).

3.3. Concomitant nasal pathologies and complications

Sixty-five patients (66.3%) were suffering from mucous-purulent rhinitis. In most subjects, this

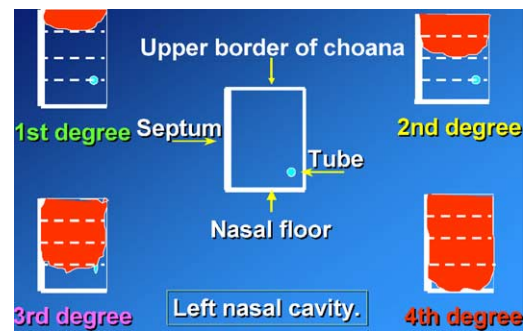


Fig. 2 Endoscopic grading of adenoid hypertrophy (left nasal cavity).

condition was confirmed by instrumental tests (rhinoscopy, fiberendoscopy). The ailment was complicated by sinusitis, radiologically revealed, in 16 patients (16.3%) (ethmoid-maxillary in 11 cases, ethmoid-frontal-maxillary in 5), and by otitis (catarrhal in 32 patients, mucous-purulent in 9) in 41 patients (41.8%) (Table 1).

Allergic rhinitis was diagnosed by prick-test and RAST in 22 patients (20.9%). The classification of the pathologic condition according to four different types of nasal obstruction is summarized in Table 1.

In the first group of eight patients, there were three cases (37%) of allergic rhinitis with turbinate hypertrophy and one case of mucous-purulent sub-chronic rhinitis with turbinate hypertrophy and plentiful exudate in the cavities.

In the second group of 20 patients, 7 cases (35%) were suffering from allergic rhinitis, 10 cases (50%) from nasal infections, complicated by sinusitis in 2 patients (10%): the objective test evidenced a considerable turbinate hypertrophy with mucous-purulent or clearly purulent secretions in the nasal cavities and rhinopharynx.

In the third group of 63 patients, only 4 cases were free from nasal pathology, 12 (19%) revealed allergic rhinitis, 47 (74.6%) showed chronic nasal infections (turbinate hypertrophy and mucous-purulent

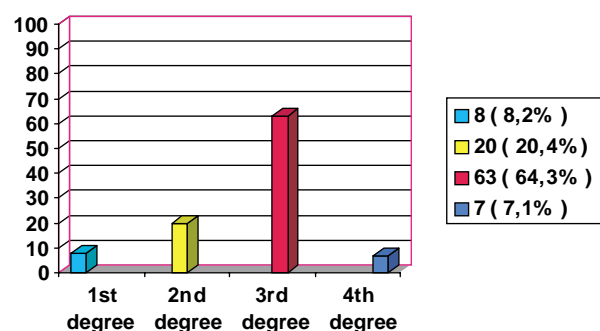


Fig. 3 Grading of adenoid hypertrophy in 98 subjects suffering from chronic nasal obstruction.

Table 1 Nasal pathology associated to adenoid hypertrophy in the study group

Adenoid hypertrophy	Muco-purulent rhinitis	Sinusitis	Otologic pathology	No pathology	Allergy
First degree (8 pz)	1 (12)	—	1 (12)	4 (50)	3 (37)
Second degree (20 pz)	10 (50)	2 (10)	5 (25)	4 (20)	7 (35)
Third degree (63 pz)	47 (74.6)	11 (17.5)	28 (44.4)	4 (6.3)	12 (19)
Fourth degree (7 pz)	7 (100)	3 (43)	7 (100)	—	—

Values in parenthesis are percentages.

exudate) while concomitant sinusitis was present in 11 cases (17.5%).

In all the patients of the last group, the nasal cavities were almost completely occupied by mucous-purulent exudate, with sinus infections present in three cases.

Otologic complications were recorded in one case (12%) with first degree obstructions (catarrhal otitis: tympanogram type B), in 5 (25%) with second degree obstructions (catarrhal otitis in 3—purulent in 2), in 28 (44.4%) with third degree obstructions (catarrhal and purulent in 8—chronic in 4), in all patients of the fourth degree obstruction group (catarrhal in 2—recurrent purulent in 3 and chronic in 2).

3.4. Rhinomanometry

Rhinomanometry investigation was performed in 7 subjects of the first degree group, in 16 of the second and in 57 of the third. In the fourth degree group rhinomanometry could not be performed owing to total obstruction of the nasal cavities (Table 2).

Normal resistances were recorded in all the cases of the first group.

In the second degree group rhinomanometry in 16 subjects revealed an increase of nasal resistance in 15 cases (93.7%). Nasal obstruction became normal after decongestion test in 14 patients; in one patient a pathologic rhinomanometry test was recorded even after decongestion, due to hyperplastic tissue and persistent turbinate hypertrophy caused by chronic sinusitis.

In the third group, the resistances resulted normal in 8 cases (14%), slightly altered in 37 (64.9%) and very high in 12 (21%).

3.5. Polysomnographic study

Full night polysomnographic study, performed in 28 patients of the third class and 7 of the fourth group, revealed an obstructive sleep apnea in 2 cases of the third and in 2 of fourth.

3.6. Therapeutic options

Patients showing first and second degree obstructions were treated with medical treatment and/or crenotherapy whereas surgery (adenoidectomy) was always performed in all fourth degree cases.

In 16 patients (25.4%) with third degree obstructions surgical intervention was deemed necessary. Twelve of these patients had rhinometric evidence of increased nasal resistances prevalently due to adenoid hypertrophy with complications which showed resistance to any medical treatment, 4 patients suffered from purulent sinusitis, 8 otitis, 2 sleep apnoeas, while 4 cases had no important nasal obstruction but other worrying complications (2 patients had chronic catarrhal otitis, 1 recurrent purulent otitis, 1 recurrent sinusitis). In 47 patients (74.6%) belonging to the third degree group, medical treatment and/or crenotherapy proved effective to control both nasal obstruction and related pathologies and complications.

Table 2 Rhinomanometry results in the study group

Nasal obstruction	Cases	Nasal resistances (Pa s/cm ³)		
		Normal (<0.280)	Quite high (0.280–0.350)	Very high (>0.350)
First degree	7	7 (100)	—	—
Second degree	16	—	14 (87.5)	1 (6.25)
Third degree	57	8 (14)	37 (64.9)	12 (21)
Fourth degree	—	—	—	—

Values in parenthesis are percentages.

Table 3 Post-adenoidectomy follow-up (after 12 months)

	Nasal obstruction	Sinusitis	Otitis	Sleep apnea
Patients	23	7	18	4
Unchanged	—	—	6 (33.3)	1 (25)
Improved	5 (21.7)	2 (28.5)	7 (38.8)	2 (50)
Resolved	18 (78.3)	5 (71.5)	5 (27.7)	1 (25)
Worsened	—	—	—	—

Values in parenthesis are percentages.

Follow-up (at least 12 months after surgery) results of the post-adenoidectomy are reported in Table 3 along with observations concerning nasal obstruction and associated complications such as sinusitis, otitis, sleep apnoeas.

4. Discussion

Many years of experience in this field have convinced us that endoscopy by means of a flexible fiberendoscope is the most reliable and easiest test to perform in pediatric age, compared with other methods usually chosen to evaluate anatomic conformation and rhinopharyngeal cavity contents (X-ray, posterior rhinoscopy, CT, telescopy) [20–23].

Endoscopy is particularly required in the definition of the obstruction degree due to adenoid growth. In fact, we classified hypertrophied adenoid obstructions into four degrees in relation both to the entity of hypertrophy and to the structure involvement. This classification, difficult to perform by other approaches, can be very useful for a therapeutic program.

Our record of the cases studied showed that disorders connected to rhinopharyngeal cavity obstruction (mucous-purulent rhinitis, sinusitis, otitis), increase in proportion to the obstruction degree and affect all the children with the most severe forms of obstruction.

Purulent sinusitis complications, usually rarer than rhinitis and otitis in pediatric age, were observed in about half of the fourth degree obstruction patients.

Sleep apnea occurred in a rather moderate percentage (6%) and only in cases with total or subtotal obstruction. This finding is in agreement with the data reported in our previous study [8], which demonstrated that adenoid hypertrophy rarely represents a determining pathogenetic factor.

Possible maxillofacial malformations connected to nasal obstructions which often have a multifactorial pathogenesis (postural, genetic, etc.) were not examined in this study.

Allergy seems not to be related to the degree of the obstruction. In fact, it was found to occur in subjects with a lower degree obstruction (Table 1). This finding seems to disprove Huang and Giannoni's report which suggested that allergy was a risk-factor for the development of adenoid hypertrophy [25].

These aforementioned findings can prove useful to program a medical or surgical therapeutic intervention.

In first and second degree obstructions, there was no indication for adenoidectomy, since the choanal openings were pervious and, as a consequence, the airflow was sometimes normal, as demonstrated, when possible, by rhinomanometric test. In these cases, the oral respiration was frequently due to habit which could be easily corrected by rehabilitation. When nasal obstruction also occurs in first and second degree subjects other nasal and rhinopharyngeal pathologies (malformations, phlogosis or neoplasm) should be suspected and ascertained.

According to other authors [26], however, drainage of nasal cavities should also be indicated in cases of low entity adenoid hypertrophy, when adenoiditis events, responsible for otitis complications, occur frequently.

In these cases, rhinopharynx infections could be well controlled by medical treatment, salsoidic and sulphurous crenotherapy and frequent cleaning of nasal cavities.

In the fourth degree obstructions, surgical treatment with adenoidectomy should be necessary [27]. However, the third degree obstructions, which affect most of our patients (65%) are undoubtedly the most complex group to treat.

Regarding obstructive problems, rhinomanometric records, performed in 57 of the 98 patients, revealed abnormal higher nasal resistances only in one-fifth of the cases; in the remaining subjects nasal resistance was just higher than normal range or completely normal.

The results of our study show that in this group the respiratory problems caused by adenoid hypertrophy may differ from subject to subject. Our findings indicate that our patients with almost similar degrees of rhinopharynx obstructions can have

completely different functional reports. The difference in nasal resistance is probably linked to other individual factors as small septal deviation, narrow nasal cavities, etc. which become important only when associated to adenoid hypertrophy.

Therapeutic strategy in third degree obstructions was decided in consideration of obstructive parameters, adenoidectomy was performed only in 21% of the cases where other minor causal factors, associated to adenoid hypertrophy: septal deviation, allergy, turbinate hypertrophy, etc., worsened the obstructive syndrome.

Decisions as to strategies to be adopted in rhinopharyngeal obstructions should be in consideration of both respiratory difficulties and local pathologies which may be caused or worsened by the hypertrophic adenoids.

In patients with third degree adenoid hypertrophy, we noticed diseases such as allergy not always related to chronic obstruction of the nasal cavities, but in many cases worsened by the obstruction. Complications due to this condition included sinusitis in 11 patients, otitis in 28, and obstructive sleep apnoea syndrome (OSAS) in 2. These situations were carefully monitored, particularly if the disorders were severe and recurrent. Such recurrent manifestations can advise adenoidectomy, when every possible treatment shows ineffective.

In mild otitis and sinusitis complications, especially if of catarrhal and transitory nature, and in non-apnoeic rhinopathies a wait and see approach is advisable; in more severe diseases such as purulent, recurrent and chronic cases, adenoidectomy should be performed without delay, even when rhinomanometric records show low nasal resistances. In fact, in these cases obstructions, associated to local phlogosis, can lead to complications.

In these patients, careful diagnostic evaluation of functional parameters (rhinomanometry, impedancemetry, audiometry, polysomnographic study) is recommend to foresee risks of important pathologies (sleep apnoea, maxillofacial malformations). In these cases, surgery is obligatory and cannot be delayed (Fig. 4).

Recourse to adenoidectomy due to complications is not very frequent in third degree, because alternative treatments can be very effective in preventing or curing pathologies and complications correlated to nasal obstruction. In our records, only in four patients surgical treatment was deemed necessary.

The results of the present study show that surgical treatment, based on obstruction degree and associated complications, is effective. In fact,

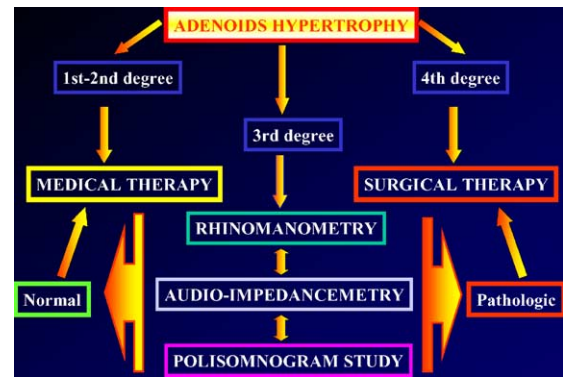


Fig. 4 Therapeutic management of the fourth degree adenoid obstructions.

nasal obstruction greatly improved or completely resolved in 100% of cases which were subjected to adenoidectomy.

Satisfactory results were obtained in cases complicated by sinusitis or otitis surgery led to cure or improvement in 100% of cases with sinusitis and positive results in 66.5% of cases in otitis.

In the latter conditions, successful treatment was achieved in recurrent acute or sub-chronic otitis, whereas chronic forms resulted unvaried because of irreversible anatomic-pathology injuries. These cases could be resolved only by tympanoplasty. Adenoidectomy is advisable also in these patients so as to avoid disease evolution and recurrence after tympanoplasty.

Less satisfying results were obtained in obstructive sleep apnoea syndrome. The condition improved partially only in two cases but no satisfactory cure of this syndrome so worrying in pediatric age seems to be available at present.

This data reported in the present paper are in agreement with research studies found in the literature which consider nasal obstruction as a secondary causal factor of OSAS, in comparison with pharyngeal obstruction due to tonsil hypertrophy.

5. Conclusions

The results of the present study indicate that fiberoendoscopy of the rhinopharyngeal cavity appears to be a reliable technique for objective evaluation of adenoid disease. This technique allowed an obstruction grading which can be used as a guide in deciding therapeutic strategy of adenoid tissue nasal obstruction. The grading can be useful in selecting the cases of real obstruction due to adenoid hypertrophy and in deciding different approaches to treatment, follow-up and cure.

Classification of obstructions through fiberendoscopy allows the selection of surgical intervention in fourth degree cases and non-surgical approaches in first and second degree cases.

The data suggest that adenoid hypertrophy with third degree obstructions have to be carefully studied so as to avoid hasty surgical decisions.

In these third degree cases, only a correct integration of objective and functional criteria and complete evaluation of complications can guide the adoption of the most appropriate therapeutic strategy.

References

- [1] P.B. Dinis, H. Haider, A. Gomes, The effects of adenoid hypertrophy and subsequent adenoidectomy on pediatric nasal airway resistance, *Am. J. Rhinol.* 13 (5) (1999) 363–369.
- [2] P.B. Van Cauwenberge, L. Bellussi, A.R. Maw, J.L. Paradise, B. Solow, The adenoid as a key factor in upper airway infections, *Int. J. Pediatr. Otorhinolaryngol.* 32 (Suppl.) (1995) S71–S80.
- [3] D. Passali, L. Bellussi, A. De Lauretis, Relapsing infective-phlogistic pathology of Waldeyer's ring and its relationship with secretory otitis media, *Acta Otolaryngol. Suppl.* 523 (1996) 138–141.
- [4] J.M. Bernstein, Waldeyer's ring and otitis media: the nasopharyngeal tonsil and otitis media, *Int. J. Pediatr. Otorhinolaryngol.* 49 (Suppl. 1) (1999) S127–S132.
- [5] P. Lavie, J. Zomer, I. Eliaschar, Z. Jochim, E. Halpern, A.H. Rubin, G. Arroy, Excessive daytime sleepiness and insomnia, *Arch. Otolaryngol.* 108 (1982) 373–377.
- [6] S. Ramakrishna, V.S. Ingle, S. Patel, P. Bhat, J.E. Dada, F.A. Shah, P.S. Murty, Reversible cardio-pulmonary changes due to adeno-tonsillar hypertrophy, *Int. J. Pediatr. Otorhinolaryngol.* 55(3) (2000) 203–206.
- [7] M.G. Lind, B.P. Lundell, Tonsillar hyperplasia in children. A cause of obstructive sleep apneas, CO₂ retention, and retarded growth, *Arch. Otolaryngol.* 108 (10) (1982) 650–654.
- [8] P. Cassano, F.M. Puca, F. Latorre, B. Brancasi, Obstructive apnea syndrome during sleep in children: diagnosis and treatment, *Acta Otorhinol. Ital.* 9 (1989) 271–279.
- [9] A.M. Levy, B.S. Tabakin, Y.S. Harrison, Hypertrophied adenoids causing hypertension and severe congestive failure, *N. Engl. J. Med.* 277 (1967) 506–511.
- [10] R.D. Olsen, E.B. Kern, P.R. Westbrook, Sleep and breathing disturbances secondary to nasal obstruction, *Otolaryngol. Head Neck Surg.* 89 (1981) 804–810.
- [11] C.W. Zwillich, C. Pickett, F.N. Hanson, Y.V. Weil, Disturbed sleep and prolonged apnea during nasal obstruction in normal men, *Am. Rev. Respir. Dis.* 124 (1981) 158–160.
- [12] P. Lavie, R. Gertner, Y. Zomer, L. Podoshin, Breathing disorders in sleep associated with "microarousals" in patients with allergic rhinitis, *Acta Otolaryngol.* 92 (1981) 529–533.
- [13] P. Cole, J.S.J. Haight, Mechanism of nasal obstruction in sleep, *Laryngoscope* 94 (1984) 1557–1559.
- [14] V.S. Dayal, E.A. Phillipson, Nasal surgery in the management of sleep apnea, *Ann. Otol.* 94 (1985) 550–554.
- [15] J.R. Mozata Nunez, M.L. Mozata Nunez, M. Mozata Nunez, S. Carrascosa Moreno, J.R. Mozata Ortiz, New indication for adenoidectomy-tonsillectomy in children: elimination of obstruction in obstructive sleep apnea syndrome, *Acta Otorrinolaringol. Esp.* 50 (1) (1999) 47–50.
- [16] G. Francois, C. Culee, Obstructive sleep apnea syndrome in infants and children, *Arch. Pediatr.* 7 (10) (2000) 1088–1102.
- [17] K. Hirth, J.T. Maurer, K. Hormann, Sleep-associated respiratory disorders in childhood, *HNO* 49 (4) (2001) 270–275.
- [18] D. Wang, P. Clement, L. Kaufman, M.P. Derde, Fiberoptic evaluation of the nasal and nasopharyngeal anatomy in children with snoring, *J. Otolaryngol.* 23 (1) (1994) 57–60.
- [19] M. Zucconi, A. Caprioglio, G. Calori, L. Ferini-Strambi, A. Oldani, C. Castronovo, S. Smirne, Craniofacial modifications in children with habitual snoring and obstructive sleep apnoea: a case-control study, *Eur. Respir. J.* 13 (2) (1999) 411–417.
- [20] G. Cantarella, G. De Berti, Evaluation of chronic nasal respiratory obstruction in children using optic fiber rhinopharyngoscopy and rhinomanometry, *Acta Otorhinol. Ital.* 10 (1990) 59–72.
- [21] D.Y. Wang, P.A. Clement, L. Kaufman, M.P. Derde, Chronic nasal obstruction in children. A fiberoptic study, *Rhinology* 33 (1) (1995) 4–6.
- [22] H. Sacre, Flexible rhinopharyngolaryngoscopy in the evaluation of patients with allergic and upper respiratory airway disorders, *Rev. Allerg. Mex.* 43 (6) (1996) 157–164.
- [23] D.Y. Wang, N. Bernheim, L. Kaufman, P. Clement, Assessment of adenoid size in children by fiberoptic examination, *Clin. Otolaryngol.* 22 (2) (1997) 172–177.
- [24] A. De Rowe, B. Forer, G. Fishman, Y. Cohen, D. Fliss, Paediatric flexible endoscope of the upper airway in the outpatient clinic, *Harefuah* 141 (5) (2002) 435–448.
- [25] S.W. Huang, C. Giannoni, The risk of adenoid hypertrophy in children with allergic rhinitis, *Ann. Allergy Asthma Immunol.* 87 (4) (2001) 350–355.
- [26] G.A. Gates, H.R. Muntz, B. Gaylis, Adenoidectomy and otitis media, *Ann. Otol. Rhinol. Laryngol.* 2 (Suppl. 155) (1991) 4–32.
- [27] C. Paulussen, J. Claes, G. Claes, M. Jorissen, Adenoids and tonsils, indications for surgery and immunological consequences of surgery, *Acta Otorhinolaryngol. Belg.* 54 (3) (2000) 403–408.

Available online at www.sciencedirect.com

SCIENCE @ DIRECT®